Review

For reprint orders, please contact: reprints@futuremedicine.com

Pain Management

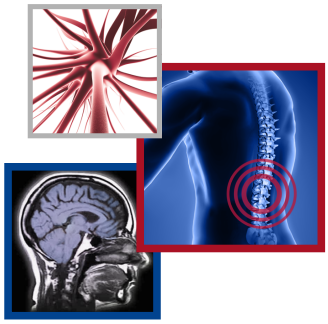

A review of the role of epidural percutaneous neuroplasty

Standiford Helm*,[1] & Nebojsa Nick Knezevic[2,3]

[1]The Helm Center for Pain Management, Laguna Woods, CA 92637, USA

[2]Vice Chair for Research & Education, Department of Anesthesiology & Pain Management, Advocate Illinois Masonic Medical Center, Chicago, IL 60657, USA

[3]Clinical Associate Professor, Department of Anesthesiology, University of Illinois, Chicago, IL 60612, USA

*Author for correspondence: drhelm@thehelmcenter.com

Practice points

Mechanism

- Neuroplasty relieves irritation of nerve roots or the intrinsic nerves of the dura, peridural membrane and posterior longitudinal ligament. This irritation may or may not be caused by scarring.
- Because relief from scarring is not always required, the procedure should be called neuroplasty rather than percutaneous adhesiolysis.
- A specific site of scarring which is refractory to other forms of treatment is the space, with a volume of about 1 ml, between the L5 and S1 nerve roots.

Indications

- Neuroplasty has been used for failed back surgery syndrome, spinal stenosis, persistent axial and radicular pain and radiculopathy. All of these diagnoses should be considered indications.

Medications

- The medications used in neuroplasty, including hypertonic saline, bupivacaine, hyaluronidase and steroids, have actions which can, by various mechanisms, inhibit the recurrence of scarring.

Procedure

- The procedure can be performed using caudal, transforaminal and interlaminar approaches and in the lumbar, thoracic and cervical regions.

Evidence

- Multiple high-quality studies have shown that neuroplasty is safe and effective.
- Recent studies indicate that the extent of stenosis is not a factor in determining the success of neuroplasty. Foraminal flow of dye is a factor associated with successful outcomes.
- Payors in the USA have been reluctant to cover the procedure. A close analysis of their rationale for not covering it fails to provide an understanding for this lack of coverage.
- Neuroplasty should be provided to patients with persistent axial and/or extremity pain who have not responded to conservative treatment before these patients are offered surgery.
- Neuroplasty should be provided to patients with spinal stenosis.
- Neuroplasty should be provided prior to most lumbar surgeries.

Degeneration, whether from age or postsurgical, in the ventral and lateral epidural space can lead to irritation of both the nerve roots and of the nerves present in the epidural space, the peridural membrane and the posterior longitudinal ligament. This irritation is often accompanied by mild scarring. Neuroplasty is a specific procedure designed to relieve this irritation. The effectiveness of neuroplasty is not affected by the extent of spinal stenosis. Neuroplasty can be performed in the lumbar, thoracic and cervical spine, and using caudal, transforaminal and interlaminar approaches. Postprocedural home exercises are an integral part of the procedure. There are multiple high-grade studies positive for the effectiveness and safety of neuroplasty. Neuroplasty should be offered prior to surgery in patients with persistent back and/or extremity pain.

First draft submitted: 7 June 2018; Accepted for publication: 9 October 2018; Published online: 3 December 2018

Keywords: epidural scarring • failed-back surgery syndrome • hyaluronidase • hypertonic saline • low back pain • nerve entrapment • neuroplasty • percutaneous adhesiolysis • peridural membrane • Racz procedure

Future Medicine

Neuroplasty, also known as percutaneous adhesiolysis or the Racz procedure, is effective in the treatment of axial and/or extremity pain which has not responded to more conservative treatment, including epidural injections. The essence of the procedure is the placement of a spring wound catheter into an area of neural irritation, often associated with mild epidural scarring, whether lumbar, thoracic or cervical, and then using a combination of hydrostatic and mechanical forces coupled with postprocedural exercises to relieve inflammation of nerves. Nerve roots are often irritated by scarring or by veins engorged by scarring, while the intrinsic nerves of the region can be inflamed with or without scarring.

History

The history of neuroplasty goes back to the late 1960s, when Hitchcock used neuraxial hypertonic saline to treat intractable pain [1–3]. In the early 1980s, Racz *et al.* described a new spring wound catheter which allowed the precise epidural placement of medications for neuroablative procedures [4,5]. As early as 1989, Racz and colleagues described the neuroplasty procedure, including at that time discussions of the need to avoid injections into loculations, to have lateral rather than midline placement, the importance of physical therapy after the procedure and the applicability of the procedure to the cervical and thoracic regions [6,7]. Racz and Heavner also attempted to point the discussion of how neuroplasty works away from solely the presence of epidural scarring towards treatment of inflamed nerves within areas of scarring [8]. Concern over either the inability to lyse dense epidural scarring and the possibility of recurrence of scarring persists to this day; the issue is whether the inflammation of nerves caused by scarring can be relieved.

Mechanism

There are multiple reasons as to why one can have refractory low back or leg pain. The most commonly considered sources of persistent pain are the facets, the sacroiliac joints and the intervertebral discs [9]. Epidural scarring is another source of low back pain. As with most sources of low back pain, estimates of the prevalence of epidural fibrosis as a cause of postlumbar surgery syndrome vary so widely as to be useless, ranging from 8 to 60% [10].

Epidural scarring is felt to cause pain in many ways. The primary hypothesis is tethering and compression of the nerves [11–15]. The pressure from the scar, along with the inflammatory factors associated with the development of the scar, can cause inflammation of the nerve root, alter the vascular supply of the nerve and change the myelin sheath [16,17]. Reduction of scarring can lead to improved functional status [18]. Pragmatically, the lysis of adhesions with an epiduroscope leads to decreased pain and increased function [19]. The role of glial cells and pericytes in scarring and pain is only now being studied [20].

Several studies have found a lack of correlation between the extent of epidural scarring, usually measured by MRI, and symptoms [21–23]. Birkenmaier *et al.* has elegantly shown that the mechanical pressures developed in neuroplasty cannot lyse dense scarring [24]. These studies, coupled with concerns that dense scarring, for example, that which maintains the integrity of a healed wound, cannot be lysed, and that scarring will recur, as after lysis of abdominal adhesions, have led to a lack of insurance coverage for neuroplasty in the USA [25]. Given the complex mechanisms by which neuroplasty works, Birkenmaier *et al.*'s study is more applicable to epiduroscopy than neuroplasty.

There is considerable evidence that the ventral epidural space and posterior longitudinal ligament are highly innervated and that inflammation or scarring in the highly innervated portions of the epidural space can lead to persistent pain [26–28]. Bosscher and Heavner have, using epiduroscopy, confirmed that the epidural space contains two types of scars. Mild scarring consists of strings or sheets of fibers which can be lysed. Severe fibrosis is dense and cannot be lysed [29]. Kobayashi *et al.* found predominantly mild adhesions in the anterior epidural space and around symptomatic nerve roots [30]. Nerve fibers are not found the dense scarring of the posterior epidural space [31]. The anterior epidural space and the posterior longitudinal ligament are highly innervated, while the posterior epidural space is not [32,33]. That ventral lateral catheter placement is associated with enhanced outcomes suggests that it is ventral lateral adhesions, rather than ventral midline, which are relevant for neuroplasty.

Kuslich *et al.*, in their seminal study on sources of pain from the lumbar spine, identified scarring between the ventral dura and the posterior longitudinal ligament, but did not highlight that scarring because they could not differentiate between pain from that scarring and pain from the annulus [34].

A specific site of scarring which can lead to lumbosacral radiculopathy has been defined by Teske *et al.* [35]. This scarring, which has been documented on cadaver studies, is specifically located between the L5 and S1 roots above the L5–S1 disc and has a volume of just over 1 ml. Called the 'scarring triangle', the space is small and would not

show up on MRI. Matsumoto [36] elegantly demonstrated that a 19G spring wound catheter could be placed into the tissue plane between L5 and S1, the posterior longitudinal ligament and the very dense scar tissue in the scarring triangle. The very dense scarring which can form in the scarring triangle can be quite clinically significant, with potential bladder dysfunction, numbness in the outer calf and, later, foot drop. Scarring between the L5 and S1 nerve roots responds poorly to conventional treatment, including epidural steroid injections, whether interlaminar or transforaminal, and surgery, including discectomy, disc replacement or fusion. This space is uniquely approached through the S1 foramen, which allows a novel application for neuroplasty. Neuroplasty of the scarring triangle between L5 and S1 can lead to rapid reversal of back pain, bladder dysfunction, numbness and foot drop.

Recent evidence suggests that the peridural membrane, an innervated structure in the infraradicular region, may also be a source of pain, particularly at L4 and L5. Furthermore, ablation of this membrane can lead to pain relief [37,38].

Veins in the foramen are easily congested, usually by bulging intervertebral discs, correlated with secondary fibrosis and neural atrophy [39–41].

Thus, scarring located both around the nerve roots, including a small, strategic space between L5 and S1, and between the posterior longitudinal ligament and the ventral dura, along with inflammation with or without scarring in the infraradicular space can all lead to persistent axial or radicular pain which can respond to neuroplasty.

Scarring can occur without surgery or any pathology other than the normal degeneration of the disc. Scar in and of itself is not innervated and scar tissue is not painful. This fact indicates that the focus should not be on scarring, but on the nerves. Unless one were to speculate that the extent of scarring was associated with the extent of compression of the nerves, it is not surprising that there is a lack of correlation between the amount of scarring and symptoms.

Thus, the putative mode of action of neuroplasty appears to not only be lysis of adhesions, freeing up and allowing nutrition to the nerve roots and uncompressing veins but also ablation of inflamed, innervated membranes. Furthermore, the target of neuroplasty is mild fibrosis, not the dense scarring which maintains the integrity of healed incisions and which can occur in the posterior epidural space. Because of the dual mode of action, including both lysis and ablation, the procedure is better referred to as neuroplasty rather than the more commonly term, percutaneous lysis of adhesions.

Indications

The literature regarding neuroplasty has evaluated multiple indications for the procedure. A recent systematic review and meta-analysis identified ten moderate- or high-quality studies of lumbar neuroplasty [11]. Indications included failed-back surgery syndrome [42,43], spinal stenosis [44], back and leg pain [45–48] and radiculopathy [49–51]. The procedure can be performed in the lumbar, thoracic and cervical regions [15]. Neuroplasty should be provided before surgery for persistent cervical, thoracic or lumbar pain, with or without radicular complaints, which has not responded to conservative therapy and for which no 'red flag' conditions exist.

Given that the concern is entrapment or irritation of a nerve root rather than scarring *per se*, it follows that the presence or absence of scarring on MRI, CT or CT myelography is not a necessary condition to perform neuroplasty. Epiduroscopy is useful tool for the diagnosis of the involved nerve root [52], but patients in the USA seldom have access to it, so that the decision to perform neuroplasty should be made on clinical grounds. Specifically, these grounds should be persistent back and/or leg pain not responsive to conservative treatment.

A useful clinical tool is the dural tug, where in the patient is placed with the legs extended on the exam table, flexed forward until the back begins to ache, then the head and neck are rapidly flexed. Replication of pain implies tethering between the dura and heavily innervated posterior longitudinal ligament [15].

Park and Moon have shown that the success of a neuroplasty procedure is not influenced by the extent of stenosis [53,54]. Park found that patients with both moderate and severe central stenosis responded well to neuroplasty; Moon's study is particularly relevant in that almost a third, 46, of his 169 patients had previously been recommended surgery. Only three had surgery at 3-month follow-up.

The critical factor appears to be contrast flow through the foramen during the procedure [28,55].

Medications

The medications used in neuroplasty have multiple potential modes of action. Hypertonic saline, which was originally used intrathecally as a neurolytic to treat chronic pain, is not neurotoxic [7]. It acts to reduce swelling in inflamed nerve roots [56,57]. It has a local anesthetic action, inhibiting compound action potentials in myelinated

fibers. Hypertonic saline also has a persistent blockade on the nonmyelinated C-fibers. This effect is felt to explanation the long-term, lasting up to years, relief of low back pain, with the inhibition of the sympathetic/sinuvertebral innervation of the epidural structures [58].

Hypertonic saline's effect on axonal action and nerve conduction may be related to both volume changes and changes in ionic concentration in the nerve root [59]. Hypertonic saline is also cytotoxic for fibroblasts at concentrations of 4% and above [60]. This finding of the inhibition of fibroblast growth is confirmed by studies showing that 5% hypertonic saline is as effective as 10% [61] and that while normal saline can produce effective pain relief in neuroplasty, patients treated with 10% saline required fewer procedures than those treated with normal saline [45,47]. Hyaluronidase's primary action is to degrade hyaluronic acid, thereby facilitating the dispersion of fluids. Hyaluronidase can also downregulate the inflammatory process inhibiting neutrophil infiltration into an inflammatory site [62] and improve outcomes after epidural steroid injections [63,64]. Hyaluronidase should also be viewed as an inhibitor of recurrent scarring and a vehicle to reduce postprocedural pain.

Bupivacaine, in addition to its local anesthetic effects, is cytotoxic for fibroblasts [60].

Steroids, while not approved by the US FDA for epidural use, are believed to have an anti-inflammatory effect, which effect includes a decrease in fibroblast formation [65]. Birkenmaier confirmed that triamcinolone had a fibroblast proliferation-retarding effect [60]. It should be noted that the predominate effect of epidural injections appears to be from the local anesthetics rather than steroids [66].

Four of the medications used in neuroplasty, hypertonic saline, bupivacaine, hyaluronidase and steroids, all have the ability to inhibit further scar formation. This *in vitro* inhibition of scar formation is supported *in vivo* by the findings of longer duration of relief with hypertonic saline.

Procedure

The formal definition of neuroplasty, as defined by the Current Procedural Terminology (CPT) is 'percutaneous lysis of epidural adhesions using solution injection, such as hypertonic saline or hyaluronidase and/or by mechanical means, with a specially designed catheter or epiduroscope'. Both single day and up to 3-day procedures are allowed. This CPT code came into existence because of the support of the late Sam Hassenbusch, a neurosurgeon who was a pioneer in the field of interventional pain management. This definition is broad and allows for multiple definitions of the procedure. It may be that a more precise CPT definition might be useful in gaining payor acceptance of the procedure.

Neuroplasty requires a specific spring wound catheter, designed to allow manipulation of the catheter through a needle without shearing and to be stiff enough to manipulate it into the desired area with minimal risk of subdural or subarachnoid placement or of damage to a nerve. Some studies have attempted to use either a nonstyleted catheter, which cannot be steered, or a nonspring wound catheter with a stylet, which can be sheared and which, being very sharp, can pierce the dura.

The procedure can be done in the lumbar, thoracic and cervical regions. Caudal, transforaminal and interlaminar approaches can be used.

The procedure was originally described with a caudal approach. The type of needle originally used, an R.K.™ needle, had a long tip which could be bent if the needle were advanced without the stylet engaged. The bent tip could catch the catheter, even though it was spring wound, leading to shearing. Currently, either a Coude needle or a radio-opaque flexible catheter is used. The flexible catheter is like an intravenous catheter in that it leaves a large plastic sheath in the sacral hiatus after the 17G introducer needle is removed. This change has systematically removed the risk of shearing. When the caudal approach is used, an entry point outside of the intertriginous area must be chosen, to minimize the risk of infection. Once inside the vertebral foramen, 5-10 cc of nonionic dye is injected. Ionic dye should not be used because of the risks associated with subarachnoid injection.

The catheter should be bent at about a 30-degree angle 2.5 cm from the tip. The catheter should be directed from the midline to the target area, avoiding rapid rotation of the catheter, rather using the bend to steer the catheter. Directing the catheter from the midline to the ventral lateral aspect of the target foramen minimizes the chance of cannulating an epidural vein. Once at the target area, nonionic contrast dye is injected. If there is no flow out the foramen or if there is venous flow, then the catheter should be manipulated in an attempt to get foraminal flow. If there is subarachnoid or subdural spread, then the procedure should be canceled and rescheduled several weeks out. If there is injection into the subdural space, the contrast should be aspirated out, which will either prevent or lead to the resolution of symptoms related to the subdural injection.

After the catheter is optimally placed, up to 1500 units of hyaluronidase in 10 cc of normal saline is injected, followed by 10 cc of a local anesthetic/steroid mixture. Preferred local anesthetics are bupivacaine 0.25% or ropivacaine 0.2%. These agents are recommended because they are unlikely to provide a motor blockade when placed in the epidural space. Avoid 2% lidocaine as it can cause a motor block if given epidurally.

The catheter is then secured and the patient taken to the recovery room and observed for signs of motor block. If there are none, then inject 1–1.5 cc of 1% preservative-free lidocaine followed by the slow injection of 10 cc of 10% saline. 10% saline can be formulated from the commercially available 23.4% saline by diluted 4.3 ml of the 23.4% saline with 5.7 ml of 1% lidocaine, creating 10 ml of 10% saline in 0.6% lidocaine. Injecting the local anesthetic prior to the hypertonic saline will prevent the pain associated with hypertonic saline injection. If a 1-day procedure is performed, the catheter is removed. If doing a two- or three-procedure, the catheter is kept in place and the hypertonic saline injection repeated daily until the procedure is complete. An alternative approach is to repeat the injections every 5–6 h for a total of three injections over 15–18 h.

Mechanical traction on the nerve root by self-directed physical therapy maneuvers, called 'neural flossing', is an integral part of the procedure. The goal of neural flossing is to ensure free movement of the nerve root and dura by breaking up scar tissue weakened by the procedure and inhibiting further scar formation. Neural flossing should be performed three to four-times a day for several months after the procedure.

If the desired nerve root cannot be reached via the caudal approach, the target nerve root and the ventral epidural space can be reached by a transforaminal approach [67]. Originally described as a supraneural procedure, because of the peridural membrane, an infraneural approach is now commonly used. If both a caudal and transforaminal approach are used, the volume of injectate can be split between the two catheters.

When neuroplasty is used to treat spinal stenosis with a positive dural tug, the caudal or S1 foraminal catheter should be augmented by a second catheter-placed transforaminally at the level of greatest stenosis.

An S1 transforaminal approach is a new development to treat scarring between the L5 and S1 root. This space can be difficult to reach with a caudal approach. This technique can be combined with an L4–5 transforaminal approach, if necessary.

Neuroplasty can also be formed in the cervical and thoracic regions, with correspondingly smaller volumes.

A concern specific to the cervical region is perivenous counter spread, in which dye is unable to flow in the lateral epidural space and takes the path of least resistance along veins to the contralateral side. This spread across the spinal cord creates the risk of spinal cord compression [68]. Flexion-rotation exercises have been described to relieve this pressure. Many practitioners incorporate these exercises immediately after cervical procedures, in addition to neural flossing.

If anesthesia is used, propofol should be avoided because of the importance of getting patient feedback of pain. The usual contraindications should be observed, including infection or bleeding disorder. Arachnoiditis and syrinx are contraindications.

Complications

A recent systematic review examined the complications associated with neuroplasty [11]. Dural puncture was the most common complication. Generally, if hypertonic saline is not administered before the dural puncture is noted, dural puncture is asymptomatic. There is one case report decreased cerebral spinal fluid pressure with a chronic subdural hematoma after dural puncture. There is also a case report of Takotsubo cardiomyopathy, or broken heart syndrome, in which stress causes cardiomyopathy, after the subarachnoid injection of 10% saline. Birkenmaier also reported cases of cauda equina syndrome in Germany and also a case of urinary incontinence in the absence of intrathecal injection [60]. This complication occurred with the midline subdural placement of the catheter, creating a mass effect on the cauda equina. Aside from this report, there are no cases of serious neurologic complications reported in the literature. The only other neurologic complications reported were transient and self limited [69,70]. Based upon Hitchcock's experience with intrathecal hypertonic saline, hypertonic saline is not unconditionally neurotoxic, although muscle weakness and sphincter disorders have been reported with its intrathecal use.

Catheter shearing, which has been reported in the past, appears to no longer be a problem with the transition from the R.K.™ needle to the Coude needle or flexible introducer catheter.

There have been no cases of epidural hematoma associated with neuroplasty.

Thus, if appropriate care is taken to avoid intrathecal injection of hypertonic saline, by careful evaluation of dye flow and by the use of local anesthetics which would not be expected to provide motor block when administered

epidurally but which would be expected to provide a motor block if administered in the subdural or subarachnoid spaces, then neuroplasty should be viewed as a safe and effective procedure with a low incidence of complications when performed by trained practitioners. Complications are generally minimal and self limited.

Evidence

Helm *et al.* evaluated the literature supporting the efficacy of neuroplasty in a systematic review and meta-analysis [11]. They identified seven randomized controlled trials (RCTs) and three observational studies. All of these studies were positive for efficacy of neuroplasty. Based solely upon the RCTs, there is strong evidence supporting the use of neuroplasty.

These RCTs have been criticized by payors for large loss to follow-up with potential selective follow-up, significant differences between the intervention and control groups at baseline, unclear adequacy of blinding, a combination of multiple treatments in the intervention and improvements in both the treatment and study arms [71]. As these criticisms were not directed to specific studies, it is difficult to respond in detail to these criticisms. In that the systematic review rated these studies on these criterion and more, it would have been useful to understand how the analyses of Helm *et al.* differed from those of the payor. One of the studies, Gerdesmeyer *et al.* [51], was of sufficient quality to warrant an editorial and to stand as a standard for a placebo-controlled study [72]. In this study, there was a 15% drop out, an acceptable rate which was sufficient to power the study. An intent-to-treat analysis was performed. There were no statistically significant differences between the placebo and treatment groups at baseline. Patients and assessing physicians were blinded. Treatment consisted of either a caudal neuroplasty procedure or subcutaneous placement of a catheter over the treatment area; there was no combination of multiple treatments. The treatment arm had a greater than 50% improvement in pain score; the placebo arm had a less than 30% improvement. In looking at these findings, the intellectual basis for the payor's criticisms are difficult to understand.

Neuroplasty continues to be met with skepticism [73], although the rationale for that skepticism has been called into question [74]. The systematic review and meta-analysis by Helm *et al.* was criticized as being written by investigators with close ties to a company which manufactures equipment used in neuroplasty. A search of a federal database [75] shows that one of the authors received royalty payments from the manufacturer. One author identified himself as a consultant for the manufacturer of products used in neuroplasty, but the federal database showed no payments to him for consulting. No authors received 'compensation for services other than consulting'. One should distinguish between royalty payments, where a company compensates the physician for the use of patents and intellectual property which the company can then use to create products for sale, and 'compensation for services other than consulting', where a company pays a physician to promote an existing product. The first activity allows the company to exist; in the second, the company is purchasing use of the physician's good will and reputation to promote products which already exist. The former is the basis of the patent system and economic growth. The latter is open to claims of conflict of interest. The basis for the suggestion that the authors were influenced by economic considerations is unclear. Reimbursement for neuroplasty has been reduced by Medicare in the USA, along with noncoverage decisions by some Medicare intermediaries. The rationale for these decisions is not clear as the evidence does not support these decisions.

The meta-analysis performed by Helm *et al.* was criticized for potentially mixing data which compared outcomes between two treatment groups with data comparing baseline to outcome within the same treatment group, a confounding which would render the meta-analysis uninterpretable. However, that was misinterpretation of how meta-analysis was described in the paper. The last two sentences of the description of how the meta-analysis could be confusing, but, due to word count limitations, not all details for the performed meta-analysis were included. All calculations were performed by meta-analysis software Review Manager (Rev Man 5.1; The Nordic Cochrane Centre, The Cochrane Collaboration, Copenhagen, Denmark, 2008). For pain and functionality improvement, the studies were reported as the standardized mean differences between baseline and certain time points (3 and 12 months) with 95% CI, regardless whether placebo or active control was used. For successful outcome data (>50% pain improvement), the studies were reported as odds ratio with 95% CI. Data were plotted using forest plots to evaluate treatment effects. Heterogeneity was interpreted through I^2 statistics. We agree with the critique that there was higher heterogeneity between the included studies; however, that is a limitation of most published studies, especially those that include chronic pain patients.

Further research since Helm's systematic review has uniformly supported the efficacy of adhesiolysis, using a variety of protocols, approaches, medications and catheters, with no unfavorable studies [28,55,76].

Thus, upon evaluating the criticisms of the evidence supporting the use of neuroplasty, the conclusion is that neuroplasty is a safe and effective procedure which should be offered to patients with persistent back and leg pain that has not responded to conservative treatment.

Conclusion

Either adhesions entrapping nerves or inflammation of structures such as the peridural membrane can cause refractory axial or extremity pain. Removal of the scarring or ablation of the inf lammed tissues by percutaneous neuroplasty can relieve this pain. Neuroplasty requires a shear-resistent, spring-wound catheter which can be steered into the appropriate tissue planes. Relief from scarring or ablation of inflamed tissues is accomplished by injection of contrast material, hyalunronidase, local anesthetic and steroid followed by hypertonic saline. A home exercise program called neural flossing is an integral portion of the procedure. The medications used in the procedure help minimize the recurrence of scarring. The procedure can be done in the lumbar, thoracic and cervical regions with caudal, transforaminal or interlaminar approaches. A novel approach to the S1 scarring triangle has been described. There is an extensive body of randomized controlled trials documenting efficacy of neuroplasty. The procedure is safe and effective. It should be provided to patients with intractable back or leg pain prior to surgery.

Future perspective

Postsurgical and age-related degeneration in the ventral and lateral epidural space can lead to irritation of both the nerve roots and the intrinsic nerves of the epidural space, the peridural space and the posterior longitudinal ligament. This irritation is often accompanied by mild scarring. Neuroplasty is a specific procedure designed to relieve this irritation of the nerves.

Neuroplasty is the subject of many high-quality studies, all of which have demonstrated efficacy and safety. Despite this overwhelming evidence, in the USA there has been reluctance by payors to support the procedure. An analysis of the reasons provided for this lack of coverage fails to provide clarity as to why coverage is not provided.

Given the drive to provide healthcare services to an expanding proportion of the population, with its imperative for approaches which are 'better, faster and cost-effective', and given the need to find methods other than opioids to control pain, neuroplasty will assume its necessary role as a procedure to offer patients with persistent axial and/or extremity pain prior to offering surgery.

Financial & competing interests disclosure

The authors have no relevant affiliations or financial involvement with any organization or entity with a financial interest in or financial conflict with the subject matter or materials discussed in the manuscript. This includes employment, consultancies, honoraria, stock ownership or options, expert testimony, grants or patents received or pending, or royalties.

No writing assistance was utilized in the production of this manuscript.

References

1 Hitchcock E. Hypothermic subarachnoid irrigation for intractable pain. *Lancet* 1133–1135 (1967).

2 Hitchcock E. Osmolytic neurolysis for intractable facial pain. *Lancet* 1(7592), 434–436 (1969).

3 Hitchcock E, Prandini MN. Hypertonic saline in management of intractable pain. *Lancet* 301(7798), 310–312 (1973).

4 Racz GB, Sabonghy M, Gintautas J, Kline WM. Intractable pain therapy using a new epidural catheter. *JAMA* 248(5), 579–581 (1982).

5 Racz G, Haynsworth RF, Lipton S. Experiences with an improved epidural catheter. *Pain Clinic* 1(1), 21–27 (1986).

6 Racz GB, Holubec JT. Lysis of adhesions in the epidural space. In: *Techniques of Neurolysis.* Racz GB (Ed.). Kluwer Press, MA, USA, 57–72 (1989).

7 Racz G, Heavner JE, Singleton W, Carline M. Hypertonic saline and corticosteroid injected epidurally for pain control. In: *Techniques of Neurolysis: Current Management of Pain.* Racz GB (Ed.). Springer Boston, MA, USA, 73–86 (1989).

8 Racz GB, Heavner J. In response to article by Drs. Devulder *et al. Clin. J. Pain* 11(2), 151–154 (1995).

9 Manchikanti L, Abdi S, Atluri S *et al.* An update of comprehensive evidence-based guidelines for interventional techniques in chronic spinal pain. Part II: guidance and recommendations. *Pain Physician* 16, S49–S283 (2013).

10 Pereira P, Severo M, Monteiro P *et al.* Results of lumbar endoscopic adhesiolysis using a radiofrequency catheter in patients with postoperative fibrosis and persistent or recurrent symptoms after discectomy. *Pain Pract.* 16(1), 67–79 (2016).

11 Helm S, Racz GB, Gerdesmeyer L *et al.* Percutaneous and endoscopic adhesiolysis in managing low back and lower extremity pain: a systematic review and meta-analysis. *Pain Physician* 19, E245–E281 (2016).

12 Kobayashi S, Kokubo Y, Uchida K *et al.* Effect of lumbar nerve root compression on primary sensory neurons and their central branches: changes in the nociceptive neuropeptides substance P and somatostatin. *Spine* 30(3), 276–282 (2005).

13 Miyamoto H, Dumas GA, Wyss UP, Ryd L. Three-dimensional analysis of the movement of lumbar spinal nerve roots in nonsimulated and simulated adhesive conditions. *Spine* 28(20), 2373–2380 (2003).

14 Hasue M. Pain and the nerve root. An interdisciplinary approach. *Spine* 18(14), 2053–2058 (1993).

15 Racz GB, Heavner JE, Noe CE *et al.* Epidural lysis of adhesions and percutaneous neuroplasty. In: *Techniques of Neurolysis, 2nd Edition.* Racz GB, Noe CE (Eds). Springer International Publishing, Switzerland, 119–143 (2016).

16 Masopust V, Hackel M, Netuka D, Bradac O, Rokyta R, Vrabec M. Postoperative epidural fibrosis. *Clin. J. Pain* 25(7), 600–606 (2009).

17 Han X, Tian X, Baklaushev V *et al.* Epidural fibrosis post laminectomy is the unappreciated cause of spinal cord compression post chronic spinal cord injury. *Biomed. Res.* 28(11), 4756–4761 (2017).

18 Liu S, Pan G, Liu G *et al.* Electrospun fibrous membranes featuring sustained release of ibuprofen reduce adhesion and improve neurological function following lumbar laminectomy. *J. Control. Release* 264, 1–13 (2017).

19 Pereira P, Severo M, Monteiro P *et al.* Results of lumbar endoscopic adhesiolysis using a radiofrequency catheter in patients with postoperative fibrosis and persistent or recurrent symptoms after discectomy. *Pain Pract.* 16(1), 67–79 (2016).

20 Lemke A, Ferguson J, Gross K *et al.* Transplantation of human amnion prevents recurring adhesions and ameliorates fibrosis in a rat model of sciatic nerve scarring. *Acta Biomater.* 66, 335–349 (2018).

21 Coskun E, Süzer T, Topuz O, Zencir M, Pakdemirli E, Tahta K. Relationships between epidural fibrosis, pain, disability, and psychological factors after lumbar disc surgery. *Eur. Spine J.* 9(3), 218–223 (2000).

22 Almeida DB, Prandini MN, Awamura Y *et al.* Outcome following lumbar disc surgery: the role of fibrosis. *Acta Neurochir.* 150(11), 1167–1176 (2008).

23 Rönnberg K, Lind B, Zoega B *et al.* Peridural scar and its relation to clinical outcome: a randomised study on surgically treated lumbar disc herniation patients. *Eur. Spine J.* 17(12), 1714–1720 (2008).

24 Birkenmaier C, Baumert S, Schroeder C, Jansson V, Wegener B. A biomechanical evaluation of the epidural neurolysis procedure. *Pain Physician* 15(1), E89–E97 (2012).

25 Nordian. Local Coverage Determination (LCD): non-covered services (L36219) (2015). https://med.noridianmedicare.com/documents/10546/6990981/Non-Covered+Services+LCD

26 Cuatico W, Parker J, Pappert E, Pilsl S. An anatomical and clinical investigation of spinal meningeal nerves. *Acta Neurochir.* 90(3–4), 139–143 (1988).

27 Parke WW, Watanabe R. Adhesions of the ventral lumbar dura. An adjunct source of discogenic pain? *Spine* 15(4), 300–303 (1990).

28 Park SH, Ji GY, Cho PG *et al.* Clinical significance of epidurography contrast patterns after adhesiolysis during lumbar percutaneous epidural neuroplasty. *Pain Res. Manag.* 2018, 6268045 (2018).

29 Bosscher H, Heavner JE. Lumbosacral epiduroscopy findings predict treatment outcome. *Pain Pract.* 14(6), 506–5014 (2014).

30 Kobayashi S, Takeno K, Yayama T *et al.* Pathomechanisms of sciatica in lumbar disc herniation: effect of periradicular adhesive tissue on electrophysiological values by an intraoperative straight leg raising test. *Spine (Phila Pa 1976)* 35(22), 2004–2014 (2010).

31 Pereira P, Avelino A, Monteiro P, Vaz R, Castro-Lopes JM. New insights from immunohistochemistry for the characterization of epidural scar tissue. *Pain physician* 17(5), 465–474 (2014).

32 Edgar M. The nerve supply of the lumbar intervertebral disc. *Bone Jt J.* 89(9), 1135–1139 (2007).

33 Groen GJ, Baljet B, Drukker J. Nerves and nerve plexuses of the human vertebral column. *Am. J Anat.* 188(3), 282–296 (1990).

34 Kuslich SD, Ulstrom CL, Michael CJ. The tissue origin of low back pain and sciatica: a report of pain response to tissue stimulation during operations on the lumbar spine using local anesthesia. *Orthop. Clin. North Am.* 22(2), 181–187 (1991).

35 Teske W, Zirke S, Nottenkämper J *et al.* Anatomical and surgical study of volume determination of the anterolateral epidural space nerve root L5/S1 under the aspect of epidural perineural injection in minimal invasive treatment of lumbar nerve root compression. *Eur. Spine J.* 20(4), 537–541 (2011).

36 Matsumoto T. Treatment of lower back and leg pain using the Racz Catheter Matsumoto way via the S1 foramen. *WIP World Congress*. Maastricht, The Netherlands (May 7-10, 2014).

37 Bosscher HA, Heavner JE. Treatment of common low back pain: a new approach to an old problem. *Pain Pract.* 15(6), 509–517 (2015).

38 Bosscher HA, Heavner JE, Grozdanov P, Warraich IA, Wachtel MS, Dertien J. The peridural membrane of the human spine is well innervated. *Anat. Rec.* 299, 484–491 (2016).

39 Hoyland JA, Freemont AJ, Jayson MI. Intervertebral foramen venous obstruction. A cause of periradicular fibrosis? *Spine* 14(6), 558–568 (1989).

40 Cooper RG, Freemont AJ, Hoyland JA *et al.* Herniated intervertebral disc-associated periradicular fibrosis and vascular abnormalities occur without inflammatory cell infiltration. *Spine* 20(5), 591–598 (1995).

41 Berthelot J-M, Le Goff B, Maugars Y. The role for radicular veins in nerve root pain is underestimated: limitations of imaging studies. *Joint Bone Spine* 78, 115–117 (2011).

42 Manchikanti L, Singh V, Cash KA, Pampati V, Datta S. A comparative effectiveness evaluation of percutaneous adhesiolysis and epidural steroid injections in managing lumbar post surgery syndrome: a randomized, equivalence controlled trial. *Pain Physician* 12(6), E355–E368 (2009).

43 Chun-Jing H, Hao-Xiong N, Jia-Xiang N. The application of percutaneous lysis of epidural adhesions in patients with failed back surgery syndrome. *Acta Cirurgica Brasileira* 27(4), 357–362 (2012).

44 Manchikanti L, Cash KA, Mcmanus CD, Pampati V, Singh V, Benyamin R. The preliminary results of a comparative effectiveness evaluation of adhesiolysis and caudal epidural injections in managing chronic low back pain secondary to spinal stenosis: a randomized, equivalence controlled trial. *Pain Physician* 12(6), E341–E354 (2009).

45 Heavner JE, Racz GB, Raj P. Percutaneous epidural neuroplasty: prospective evaluation of 0.9% NaCl versus 10% NaCl with or without hyaluronidase. *Reg. Anesth. Pain Med.* 24(3), 202–207 (1999).

46 Manchikanti L, Pakanati RR, Bakhit CE, Pampati V. Role of adhesiolysis and hypertonic saline neurolysis in management of low back pain: evaluation of modification of the Racz protocol. *Pain Digest.* 9(2), 91–96 (1999).

47 Manchikanti L, Rivera JJ, Pampati V *et al.* One day lumbar epidural adhesiolysis and hypertonic saline neurolysis in treatment of chronic low back pain: a randomized, double-blind trial. *Pain Physician* 7(2), 177–186 (2004).

48 Oh CH, Ji JY, Cho PG *et al.* The catheter tip position and effects of percutaneous epidural neuroplasty in patients with lumbar disc disease during 6-months of follow-up. *Pain Physician* 17, E599–E608 (2014).

49 Gerdesmeyer L, Lampe R, Veihelmann A *et al.* Chronic radiculopathy. Use of minimally invasive percutaneous epidural neurolysis according to Racz. *Schmerz* 19(4), 285–295 (2005).

50 Veihelmann A, Devens C, Trouillier H, Birkenmaier C, Gerdesmeyer L, Refior HJ. Epidural neuroplasty versus physiotherapy to relieve pain in patients with sciatica: a prospective randomized blinded clinical trial. *J. Orthop. Sci.* 11(4), 365–369 (2006).

51 Gerdesmeyer L, Wagenpfeil S, Birkenmaier C *et al.* Percutaneous epidural lysis of adhesions in chronic lumbar radicular pain: a randomized, double-blind, placebo-controlled trial. *Pain Physician* 16(3), 185–196 (2013).

52 Bosscher HA, Heavner JE. Diagnosis of the vertebral level from which low back or leg pain originates. A comparison of clinical evaluation, MRI and epiduroscopy. *Pain Pract.* 12(7), 506–512 (2012).

53 Park CH, Lee S-H, Lee S-C. Preliminary results of the clinical effectiveness of percutaneous adhesiolysis using a Racz catheter in the management of chronic pain due to cervical central stenosis. *Pain Physician* 16(4), 353–358 (2013).

54 Moon DE, Kim YH, Seocho-Gu S. Assessment of clinical outcomes of cervical epidural neuroplasty using a racz-catheter and predictive factors of efficacy in patients with cervical spinal pain. *Pain Physician* 18, E163–E170 (2015).

55 Han Y-J, Lee MN, Cho MJ, Park HJ, Moon DE, Kim YH. Contrast runoff correlates with the clinical outcome of cervical epidural neuroplasty using a Racz catheter. *Pain Physician* 19(7), E1035–E1040 (2016).

56 Jewett DL, King JS. Conduction block of monkey dorsal rootlets by water and hypertonic saline solutions. *Exp. Neurol.* 33(1), 225–237 (1971).

57 Rojiani AM, Cho ES, Sharer L, Prineas JW. Electrolyte-induced demyelination in rats. 2. Ultrastructural evolution. *Acta Neuropathol.* 88(4), 293–299 (1994).

58 King JS, Jewett DL, Sundberg HR. Differential blockade of cat dorsal root C fibers by various chloride solutions. *J. Neurosurg.* 36(5), 569–583 (1972).

59 Kukita F, Yamagishi S. Excitation of squid giant axons in hypotonic and hypertonic solutions. *Jpn J. Physiol.* 29(6), 669–681 (1979).

60 Birkenmaier C, Redeker J, Sievers B, Melcher C, Jansson V, Mayer-Wagner S. An evaluation of medications commonly used for epidural neurolysis procedures in a human fibroblast cell culture model. *Reg. Anesth. Pain Med.* 36(2), 140–144 (2011).

61 Choi EJ, Yoo YJ, Lee PB, Kim Y-C, Lee SC, Moon JY. A retrospective study to evaluate the effect of concentration of hypertonic saline on efficacy and safety of epidural adhesiolysis. *Anesth. Analg.* 124(6), 2021–2029 (2017).

62 Fronza M, Muhr C, Calheiros Da Silveira DS *et al.* Hyaluronidase decreases neutrophils infiltration to the inflammatory site. *Inflamm. Res.* 65(7), 533–542 (2016).

63 Kim SB, Lee KW, Lee JH, Kim MA, Kim BH. The additional effect of hyaluronidase in lumbar interlaminar epidural injection. *Ann. Rrehabil. Med.* 35(3), 405–411 (2011).

64 Yousef AA, As EL-D, Al-Deeb AE. The role of adding hyaluronidase to fluoroscopically guided caudal steroid and hypertonic saline injection in patients with failed back surgery syndrome: a prospective, double-blinded, randomized study. *Pain Pract.* 10(6), 548–553 (2010).

65 Baqai A, Bal R. The mechanism of action and side effects of epidural steroids. *Tech. Reg. Anesth. Pain Manag.* 13(4), 205–211 (2009).

66 Manchikanti L, Singh V, Cash KA, Pampati V, Falco FJ. A randomized, double-blind, active-control trial of the effectiveness of lumbar interlaminar epidural injections in disc herniation. *Pain Physician* 17(1), E61–E74 (2014).

67 Hammer M, Doleys DM, Yung CO. Transforaminal ventral epidural adhesiolysis. *Pain Physician* 4(3), 273–279 (2001).

68 Racz GB, Heavner JE. Cervical spinal canal loculation and secondary ischemic cord injury – pvcs – perivenous counter spread – danger sign! *Pain Pract.* 8(5), 399–403 (2008).

69 Wagner K, Sprenger T, Pecho C *et al.* Risks and complications of epidural neurolysis–a review with case report. *Anasthesiol. Intensivmed. Notfallmed. Schmerzther.* 41(4), 213–222 (2006).

70 Talu GK, Erdine S. Complications of epidural neuroplasty: a retrospective evaluation. *Neuromodulation* 6(4), 237–247 (2003).

71 Gerrard P. Medically not necessary determination of percutaneous adhesiolysis CPT 62264. (2018).

72 Helm S, 2nd, Benyamin RM, Falco FJ. Refinement in evidence synthesis of percutaneous adhesiolysis. *Pain Physician* 16(3), 177–183 (2013).

73 Bhatia A, Nelson A, Cohen SP. Breaking bad (tissue): epidural adhesiolysis and its outcomes. *Anesth. Analg.* 124(6), 1755–1777 (2017).

74 Racz G, Candido K, Helm S. Neuroplasty is a safe, effective procedure. *Anesth. Analg.* 126(1), 363 (2017).

75 Fillingim RB, Kaplan L, Staud R *et al.* The A118G single nucleotide polymorphism of the opioid receptor gene (OPRM1) is associated with pressure pain sensitivity in humans. *J. Pain* 6(3), 159–167 (2005).

76 Aoi I, Chen HC, Lui TN, Lin TJ. Outcomes of epidural neuroplasty utilizing adhesiolysis by means of hydraulic and mechanical force. *J. Biomed.* 3, 26–31 (2018).